

# Self-expanding metal stents in the palliative treatment of colon cancer. Results of 10 years of experience

Gastón Jury, Rafael López Fagalde, Leandro Amieva, Gonzalo Ramacciotti, Leandro Manzotti, Martín Dolan, Victoria Sayanes, Diego Miconi, Nicolás Ruiz, Diego Naiderman

Centro de Estudios Digestivos, Mar del Plata, Pcia de Buenos Aires, Argentina.

## ABSTRACT

**Introduction:** endoscopic placement of self-expanding metal stents (SEMS) emerges as a therapeutic option for neoplastic obstruction of the colon in two situations: as palliative treatment and as a bridge to curative surgery. This procedure avoids two-stage surgeries and reduces the probability of permanent colostomy and its complications with the consequent deterioration in quality of life.

**Objective:** to report our experience in the placement of SEMS as palliative treatment in neoplastic colorectal obstruction.

**Design:** retrospective, longitudinal, descriptive and observational study.

**Methods:** all patients in whom the same group of endoscopists performed SEMS placement with palliative intent for advanced colorectal cancer between August 2008 and December 2019 were analyzed. Data collected were demographic and clinical variables, technical and clinical success, early and late complications, and survival.

**Results:** SEMS were placed in 54 patients. The average age was 71 years. Eighty-five percent were left-sided tumors. In 57% of the patients the procedure was performed on an outpatient basis. Technical and clinical success was 92 and 90%, respectively, and median survival was 209 days. The complication rate was 29.6%, including 14.8% obstruction and 5.6% migration. Late mortality attributable to the procedure was 5.6%, caused by 3 late perforations: 2 open and 1 microperforation with localized abscess formation.

**Conclusions:** The placement of SEMS as a palliative treatment for neoplastic colonic obstruction is feasible, effective and safe. It allowed outpatient management or brief hospitalization and early refeeding, improving the conditions to face an eventual palliative chemotherapy treatment. Most complications were late and resolved endoscopically on an outpatient basis.

**Keywords:** colorectal cancer, self-expanding metal colonic stents, colorectal neoplastic obstruction, palliative treatment

## INTRODUCTION

Colorectal cancer (CRC) is one of the most common tumors worldwide. In Argentina it occupies second place, both in prevalence and mortality from cancer in both sexes, with approximately 7,000 deaths annually.<sup>1</sup>

Obstruction due to advanced CRC occurs in 8 to 13% of patients and represents an emergency in gastroenterology that requires immediate treatment.<sup>2</sup> If not treated adequately; it can lead to electrolyte imbalance, bacterial translocation, colonic necrosis, and death. The classic treatment consists of emergency surgery and diverting ostomy, with or without tumor resection. In this scenario, morbidity and mortality is higher than in elective surgery.<sup>3,4</sup> Almost 30% of patients do not undergo restoration of bowel transit, which implies considering ostomy complications and deterioration in quality of life.<sup>3-5</sup>

In 1991, the use of self-expanding metal stents (SEMS) was described as a feasible and safe alternative for neoplastic colonic obstruction in two specific situations. First, as palliative treatment in patients without the possibility of curative surgical treatment and second, as a bridge to sur-

gery.<sup>6</sup> In this last situation, the placement of SEMS resolves the acute obstructive condition, allowing intestinal preparation and subsequent oncologic staging. In this way, emergency surgery and subsequent colostomy are avoided.<sup>7</sup>

In Argentina, the literature on this topic is minimal,<sup>8,9</sup> so the objective of this publication is to present our experience in the palliative treatment of obstructive CRC with SEMS in a monovalent center specialized in gastroenterology and proctology of the city of Mar del Plata. It should be noted that our institution receives patients from regional hospitals and centers that do not have the experience or technology to perform this type of procedures, which require specific training, availability of colonic stents (stock), radiology equipment and adequate material.

## MATERIAL AND METHODS

### Population

All patients with neoplastic rectocolonic sub-obstruction or obstruction, who underwent SEMS placement with palliative intent between August 2008 and December 2019, were included. The diagnosis was made with clinical and radiological parameters. None of the patients presented with an acute perforative abdomen nor were they candidates for surgery in a single stage. All procedures were performed by gastroenterologists or coloproctologists with experience in endoscopy. Self-expanding nitinol stents were used, and placed under endoscopic vision and simultaneous radioscopy control. Patients who underwent SEMS placement as a surgical bridge, and those with benign strictures (post-surgical, due to endometriosis or diverticular disease) or with extrinsic compressions were excluded.

The following variables were analyzed: demographic and clinical characteristics, ASA classification (surgical risk according to the guidelines of the American Society of Anesthesiologists), clinical success (defined as colonic decompression and resolution of occlusive symptoms within 96 hours after the procedure, without endoscopic intervention or surgical reintervention), technical success (defined as the placement and deployment of the stent through the tumor with dilation of the stenosis, confirmed under fluoroscopic vision), early and late complications (obstruction, bleeding, perforation, migration and pain), location of the tumor, duration of the procedure, modality (outpatient or inpatient), characteristics of the stent (material, length and type of coverage – uncovered, semi-covered or fully covered) and survival.

By convention, we define early complications as those that occur within 7 days of SEMS placement and late complications as those that occur after 7 days.

The authors declare no conflicts of interest. **Gastón Jury:** [gljury@hotmail.com](mailto:gljury@hotmail.com)  
Received: November 2020. Accepted: July 2022.

Gastón Jury: <https://orcid.org/0000-0001-8509-4154>, Rafael López Fagalde: <https://orcid.org/0000-0002-9582-5691>, Leandro Amieva: <https://orcid.org/0000-0002123-061x>, Gonzalo Ramacciotti: <https://orcid.org/0000-0003-3926-564x>, Leandro Manzotti: <https://orcid.org/0000-0002-5824-1144>, Martín Dolan: <https://orcid.org/0000-000236736920>, Victoria Sayanes: <https://orcid.org/0000-00023293-3599>, Diego Miconi: <https://orcid.org/0000-0001-8259-9528>, Nicolás Ruiz: <https://orcid.org/0000-0001-6725-2948>, Diego Naiderman: <https://orcid.org/0000-000349900141>.

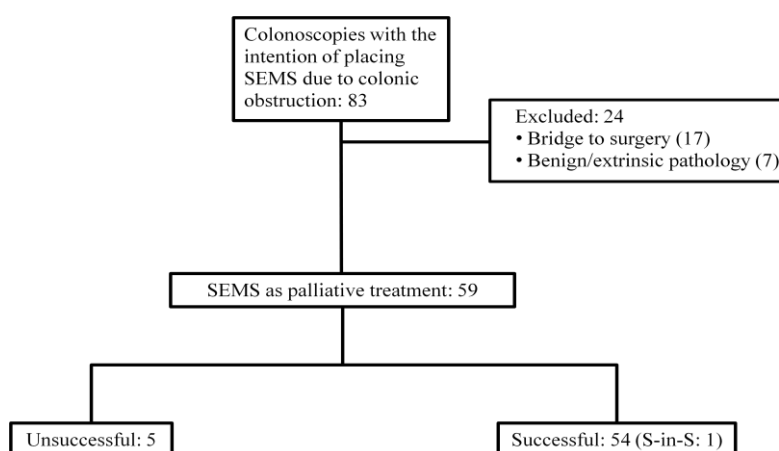
## Procedure

After colon cleansing with enemas, endoscopy was performed with an Olympus® 145-160-170 series video colonoscope with 4.2 mm working channel, or an Olympus® 100 series dual-channel therapeutic video colonoscope, depending on the location of the tumor. Under fluoroscopic vision, colography with water-soluble contrast (Triyoson®) was performed in all cases to characterize the stenosis and decide the length of the stent. The stenosis was then crossed with a hydrophilic guidewire (Hidra Jagwire® Boston Scientific) through the working channel and the stent delivery system was passed over the guidewire, always through the endoscope. Under endoscopic and radioscopy vision, the stent was placed using the minimum possible insufflation. It began with its release and expansion from proximal to distal, observing the deployment, with the possibility of repositioning it, until its complete release.

Once released, a slight expansion was awaited and then the introducer system and the guide were removed always under radioscopy and endoscopic surveillance. All procedures were performed under deep sedation with Propofol, administered by an anesthesiologist.

## RESULTS

Eighty-three colonoscopies were performed with the intent of placing SEMS to resolve colonic obstruction (Fig. 1). Seventeen procedures in which SEMS were placed as a bridge to surgery and 7 procedures in patients with benign or extrinsic compression were rule out. Of the remaining 59 patients in whom the procedure was performed with palliative intent, SEMS could be placed in 54 (1 stent-in-stent), with placement not achieved in 5 (8.5%).



**Figure 1.** Flowchart of the study participants. SEMS: self-expanding metal stents. S-in-S: Stent in stent.

The average age of the patients was  $71 \pm 15$  (range 34-94) years and 57% were men. 51 percent had ASA 3 surgical risk. Forty-two patients (78%) presented symptoms of large-bowel sub-obstruction, 10 (18%) had complete obstruction and 2 reported tenesmus as the only symptom (tumor located in the middle-lower rectum). A patient who was admitted asymptomatic for routine colonoscopy presented air trapping due to the valvular mechanism of a colon neoplasm that was immediately resolved with the placement of a stent. Eighty-five percent of tumors (46) were located in the left colon and rectum (Table 1).

The average procedure time was  $26.5 \pm 15$  (range: 7-80) minutes. A total of 54 SEMS were placed, 25 of 60 x 25 mm (46%), 19 of 90 x 25 mm (35%), 9 of 120 x 25 mm (5%) and a 120 x 18 mm covered esophageal prosthesis inside a previous stent (stent-in-stent). In no case was it necessary to perform dilations before stent placement (Table 2).

In 31 (57%) patients, the procedure was performed on an outpatient basis and in the rest it was performed in a hospital setting, with an average of 2.5 (range: 1-8) days of hospitalization. Local or distant advanced disease was recorded with some diagnostic imaging method in 40 (74%) patients: 29 liver metastases, 8 peritoneal carcinomatosis, 1 bladder infiltration, 1 cologastric fistula, and 1 recurrence after

previous surgery with lymph nodes conglomerates and pulmonary metastases.

Technical success was achieved in 54 out of 59 procedures (92%). In 5 patients the stent could not be placed, in 3 of them it was not possible to pass the thread or contrast through the stenosis, in one the long and irregular stenosis prevented the advancement of the stent, and another had a double stenosis that prevented passage through the distal stenosis.

Clinical success occurred in 53 (90%) patients since one patient had a cologastric fistula that caused proximal migration of the stent and had to be resolved with resection surgery (Table 2).

All patients started early feeding within 24 hours of SEMS placement. No major complications such as death, bleeding, perforation, or associated thrombotic events occurred within 7 days of the procedure.

Survival time was recorded in 47 out of 53 patients (89%) with clinical success. The mean time from SEMS placement to death was 209 (range: 3-805) days. Thirty-four percent lived less than two months, 45% between 2 and 12 months and 21% more than a year (Table 3).

**Table 1.** Demographic data, length of hospitalization, symptoms and location of lesions found in patients with successful placement of self-expanding metal stents.

|                                   |            |
|-----------------------------------|------------|
| Patients: n                       | 54         |
| Age (years): median (range)       | 71 (34-94) |
| Gender: M:F                       | 31:23      |
| Procedure: n (%)                  |            |
| Outpatient                        | 31 (57)    |
| Inpatient                         | 23 (43)    |
| Length of (days): average (range) | 2,5 (1-8)  |
| Presenting symptoms: n (%)        |            |
| Sub-obstruction                   | 42 (78)    |
| Obstruction                       | 10 (18)    |
| Tenesmus/other                    | 2 (4)      |
| Location of the stenosis          |            |
| Rectum                            | 8          |
| Rectosigmoid junction             | 18         |
| Sigmoid colon                     | 14         |
| Descending colon                  | 6          |
| Splenic flexure                   | 3          |
| Transverse colon                  | 2          |
| Hepatic flexure                   | 3          |

The 16 (34%) patients who underwent chemotherapy had mean survival of 379 days, while it was 167 days in those not treated.

Sixteen (29.6%) patients presented complications associated with the procedure. There were 2 (3.7%) patients with early complications, both due to early stent migrations and 14 (25.9%) with late complications.

**Table 2.** Variables of the placement of the self-expanding metal colonic stent.

| Variables               | n = 59      |
|-------------------------|-------------|
| Time, min: mean (range) | 26,5 (7-80) |
| Stent length, mm: n     |             |
| 60x25                   | 25          |
| 90x25                   | 19          |
| 120x25                  | 9           |
| 120x18 (esophageal)     | 1           |
| Technical success n (%) | 54 (92)     |
| Clinical success n (%)  | 53 (90)     |

There were 3 (5.6%) stent migrations, 2 (3.7%) distal: one of them 72 hours after placement that was resolved with endoscopic replacement of the same stent and another in which the absence of the stent was noted in the computed tomography during oncologic follow-up. This patient did not require any treatment and had a survival of 605 days. One (1.9%) proximal migration through the cologastric fistula was resolved by resection surgery.

There were 2 (3.7%) open perforations that were diagnosed at 498 and 187 days and caused the death of the patients. The patient who lived 498 days received chemotherapy treatment and one later had a stent obstruction that required a new stent. Six months later he was admitted with an acute abdomen, with perforation and subsequent death. The other patient, with lung and liver metastases, was admitted with an acute abdomen. A bowel perforation was diagnosed by CT and he died 4 days later.

One patient (1.9%) required hospitalization 8 months after the procedure due to a peri stent abscess. Since her performance status due to disease progression did not allow surgical treatment, she underwent medical treatment and died after 4 days.

Stent obstruction occurred in 8 (14.8%) patients, which was resolved endoscopically in 6. Five underwent placement of a second stent (S-in-S) and one underwent argon plasma ablation. Two other obstructions caused by fecal impaction improved with enemas.

Two (3.7%) patients presented tenesmus and pain, one resolved spontaneously and the other with opiates (Table 4).

Late mortality due to the procedure occurred in 3 (5.6%) patients, in all cases due to perforation (2 open perforations and 1 microperforation with localized abscess formation).

**Table 3.** Survival time in 47 patients with self-expanding metal colonic stents.

| Survival (days) | Patients n (%) |
|-----------------|----------------|
| <60             | 16 (34)        |
| 60-120          | 7 (15)         |
| 120-240         | 8 (17)         |
| 240-360         | 6 (13)         |
| 360-720         | 6 (13)         |
| >720            | 4 (8)          |

**Table 4.** Complications after successful placement of self-expanding metal stents, and their treatment.

| Complications            | n (%)     | Resolution  |
|--------------------------|-----------|---|
| Stent obstruction        | 8 (14,8)  | S-in-S: 5<br>Argon plasma tunneling: 1<br>Enemas: 2 |
| Distal stent migration   | 2 (3,7)   | Stent repositioning: 1<br>Spontaneous: 1            |
| Proximal stent migration | 1 (1,9)   | Surgery   |
| Perforation              | 2 (3,7)   | Medical treatment and death                         |
| Tenesmus and pain        | 2 (3,7)   | Opioids: 1<br>Spontaneous: 1                        |
| Peri stent abscess       | 1 (1,9)   | Medical treatment and death                         |
| Total                    | 16 (29,6) |   |

S-in-S: stent in stent.

## DISCUSSION

Acute colonic obstruction is part of acute abdomen syndrome and must be resolved urgently. Traditionally, the only treatment option was surgery, which has high morbidity and mortality (5-15% and up to 35%, respectively). This may be due to several factors such as advanced age, multiple comorbidities, advanced stage disease, malnutrition, and lack of colonic preparation with contamination of the surgical field. Resolution of the acute condition involves a decompressive ostomy with or without resection of the tumor in the first stage and a subsequent bowel transit reconstruction, if possible. However, 25% of ostomies with temporary intent remain permanently, which affects the quality of life of these patients.<sup>10,11</sup>

The guidelines of the European Society of Digestive Endoscopy promote the placement of SEMS as palliative treatment with a high level of evidence and recommendation, since it reduces the rate of colostomies and improves quality of life, with a morbidity similar to surgery.<sup>2</sup>

We understand that this subgroup of patients with advanced colon cancer undergoing palliative treatment, who present heterogeneity in the tumor burden in terms of the location of the metastases (hepatic, peritoneal, lung, etc.), are not candidates for resection of the primary tumor. These patients are treated with chemotherapy and if they cannot receive it they have a much worse survival than other CRC patients.

A notable fact in our series is the performance of almost 60% of the procedures on an outpatient basis with a quick return home, which directly impacts the quality of life of our patients. Furthermore, it affects hospitalization costs and therefore overall costs. On the other hand, in patients who required hospitalization, the average length of stay was 2.5 days, which reduced expenses and exposure to in-hospital complications.<sup>12</sup>

The most frequent form of presentation was bowel obstruction, which allowed "elective" placement of the stent. These patients assisted to the center on their own and left hours after the procedure. In all cases, the symptoms were resolved without the need for prolonged hospitalization or complex surgeries.<sup>13</sup>

It should be noted that the complications (29.6%) that our patients presented were mostly late. Almost all resolved through medical or endoscopic treatment, allowing outpatient management. The serious complications, which were perforating and culminated in the death of the patient, occurred after 6 months and we believe that they are related to the evolution of the underlying neoplastic disease.

The mean survival was 209 days (3-805), in 41% of patients over 6 months. The highest mortality (34%) occurred in the first two months. Patients who received chemotherapy had an average survival of 379 days compared to 167 days in those who did not receive it. This allows us to affirm, even with all types of biases, that oncologic treatment would prolong survival in this population subgroup.<sup>14</sup>

We believe that performing outpatient or short-stay practices improves the quality of life of patients. Although this aspect is evaluated only objectively through surveys such as the QLQ C-29, a specific module for CRC, the analysis of our series shows that patients receive early feeding, within 24 hours after SEMS placement, and can quickly return home. Both situations allow for early initiation of oncologic treatment, which also influences an improvement in quality of life and an increase in survival.<sup>15-17</sup>

The present study has limitations. Among them, the collection of some data from patients in neighboring towns or from local health centers that do not have computerized systems.

Prospective, randomized studies with a larger number of patients will be necessary to confirm the good results of SEMS placement for the resolution of CRC obstruction in patients with an indication for palliative treatment.

## CONCLUSIONS

This study confirms that the use of SEMS as palliative treatment of neoplastic colonic obstruction is feasible, effective and safe. It allowed outpatient management or brief hospitalization and early refeeding, improving the conditions to face an eventual palliative chemotherapy treatment. Most complications were late and were successfully resolved by endoscopy on an outpatient basis.

## REFERENCES

- Instituto nacional del cáncer (INC). Ministerio de Salud de la Nación Sección Estadística –Mortalidad de CCR 2017; Argentina.gob.ar.
- van Hooff JE, Veld JV, Arnold D, Beets-Tan RGH, Everett S, Götz M, et al. Self-expandable metal stents for obstructing colonic and extracolonic cancer: European Society of Gastrointestinal Endoscopy (ESGE) Guideline - Update 2020. *Endoscopy*. 2020; 52:389-407.
- Parkin DM, Bray F, Ferlay J, Pisani P. Global cancer statistics, 2002. *CA Cancer J Clin*. 2005; 55:74-108.
- Iversen LH, Bülow S, Christensen JJ, Laurberg S, Harling H, Danish Colorectal Cancer Group. Postoperative medical complications are the main cause of early death after emergency surgery for colonic cancer. *Br J Surg*. 2008; 95:1012-19.
- Wong RW, Rappaport WD, Witzke DB, Putnam CW, Hunter GC. Factors influencing the safety of colostomy closure in the elderly. *J Surg Res*. 1994; 57:289-92.
- M. Dohmoto. New method: endoscopic implantation of rectal stent in palliative treatment of malignant stenosis. *Endoscopy Digest*. 1991; 3:1507-12.
- Singh H, Latosinsky S, Spiegel BM, Targownik LE. The cost-effectiveness of colonic stenting as a bridge to curative surgery in patients with acute left-sided malignant colonic obstruction: a Canadian perspective. *Can J Gastroenterol*. 2006; 20:779-85.
- Jury G, Amieva L, Dolan M, López Fagalde R, Naiderman D, Pastorino M, et al. Obstrucción neoplásica de colon: Tratamiento con prótesis autoexpansibles. *Acta Gastroenterol Latinoam*. 2014; 44:33-8.
- Alvarez Gallesio JM, Bun M, Pereyra L, Schlottmann F, Mella JM, Peczan C, et al. Resultados de la colocación de stents autoexpansibles en el tratamiento de la obstrucción colorrectal. Neoplasia intrínseca vs. extrínseca. *Acta Gastroenterol Latinoam*. 2018; 48:117-23.
- Buechter KJ, Boustany C, Caillouette R, Cohn I Jr. Surgical management of the acutely obstructed colon. A review of 127 cases. *Am J Surg*. 1988; 156 (3 Pt 1):163-68.
- Arezzo A, Balague C, Targarona E, Borghi F, Giraudo G, Ghezzi L, et al. Colonic stenting as a bridge to surgery versus emergency surgery for malignant colonic obstruction: results of a multicentre randomised controlled trial (ESCO trial). *Surg Endosc*. 2017; 31:3297-5.
- Xinopoulos D, Dimitroulopoulos D, Theodosopoulos T, Tsamakidis K, Bitsakou G, Plataniotis G, et al. Stenting or stoma creation for patients with inoperable malignant colonic obstructions? Results of a study and cost-effectiveness analysis. *Surg Endosc*. 200; 18:421-26.
- Ohki T, Yoshida S, Yamamoto M, Isayama H, Yamada T, Matsuzawa T, et al. Determining the difference in the efficacy and safety of self-expandable metallic stents as a bridge to surgery for obstructive colon cancer among patients in the CROSS 0 group and those in the CROSS 1 or 2 group: a pooled analysis of data from two Japanese prospective multicenter trials. *Surg Today*. 2020; 50:984-94.
- Lee HJ, Hong SP, Cheon JH, Kim TI, Min BS, Kim NK, et al. Long-term outcome of palliative therapy for malignant colorectal obstruction in patients with unresectable metastatic colorectal cancers: endoscopic stenting versus surgery. *Gastrointest Endosc*. 2011; 73:535-42.
- Saida Y. Current status of colonic stent for obstructive colorectal cancer in Japan; a review of the literature. *J Anus Rectum Colon*. 2019; 3:99-105.
- Takahashi H, Okabayashi K, Tsuruta M, Hasegawa H, Yahagi M, Kitagawa Y. Self-expanding metallic stents versus surgical intervention as palliative therapy for obstructive colorectal cancer: a meta-analysis. *World J Surg*. 2015; 39:2037-44.
- Young CJ, De-Loyde KJ, Young JM, Solomon MJ, Chew EH, Byrne CM, et al. Improving quality of life for people with incurable large-bowel obstruction: randomized control trial of colonic stent insertion. *Dis Colon Rectum*. 2015; 58:838-49.