

# Dufourmental flap in pilonidal disease

Ignacio F. Ramallo, Eliomar Aguilar, Dayana Naranjo

General Surgery Service, Coloproctology Section, Hospital Naval Puerto Belgrano, Punta Alta, Provincia de Buenos Aires

## ABSTRACT

**Introduction:** Pilonidal disease is a pathology located in the sacrococcygeal region caused by hair entering the subcutaneous cellular tissue forming sinus tracts. There are different resection surgical techniques for its treatment, including Dufourmental, resection and closure outside the midline using dermocutaneous flaps.

**Objective:** To evaluate the results of resection and primary closure with Dufourmental flap for pilonidal disease.

**Design:** Retrospective case series.

**Material and methods:** Patients with sacrococcygeal cyst operated by resection and closure with Dufourmental flap were included, between 2020 and 2021. Demographic variables, presentation of the disease, operative time, hospital stay, postoperative pain, postoperative complications, recovery time, healing, return to activities and recurrence were evaluated.

**Results:** 10 patients (8 men) with a median age of 21.5 (range: 16-27) years were included. Two patients had recurrent disease, 3 had had abscesses drained, and 1 had an associated perianal fistula. The average operative time was 64 minutes and the median hospital stay was 1 day. Morbidity was 20%: 1 infection of the surgical site with subsequent dehiscence of 50% of the wound and 1 necrosis of 5% of the upper edge of the flap associated with a granuloma in said region. Postoperative pain was minimal, the median time to return to work was 21.1 (range: 17-30) days. There were no recurrences during an 18-month follow-up.

**Conclusions:** The Dufourmental flap is a technique that was associated in our population with low postoperative pain and a low recurrence rate. A larger number of cases is required to generalize these results.

**Keywords:** sacrococcygeal cyst, pilonidal disease, Dufourmental flap

## INTRODUCTION

Pilonidal sinus disease is a common benign skin condition located in the sacrococcygeal region that can be acute or chronic.<sup>1</sup> The first presentation is attributed to Mayo in 1833.<sup>2</sup>

According to Karydakos,<sup>3</sup> there are 3 factors that contribute to its appearance: 1) the presence of loose hair, 2) an external force that causes the insertion of the hair into the subcutaneous tissue (micro trauma) and 3) the "vulnerability" of the skin produced by the maceration and depth of the natal cleft. It has a prevalence of 26/100,000 people with a male: female ratio of 2.2:1 and mostly affects young adults. The most relevant predisposing factors are obesity, hirsutism and depth of the intergluteal cleft. Pathophysiologically, it is characterized by the ingress of hair into the subcutaneous cellular tissue, favored by microtraumas on this area, generating a pseudocyst of granulation tissue with hairs without bulbs inside.<sup>4,5</sup>

Surgical treatment is preferred over conservative treatment. There are non-resective surgical techniques, where the sinus

is unroofed and healing occurs by secondary intention, to those that involve total resection with or without closure of the defect. The use of dermocutaneous flaps is a widely described option for the primary closure of large defects outside the midline, of which the Limberg flap and its Dufourmental variant are the most commonly used.<sup>1,4,6,7</sup> None of the described techniques eliminates the risk of recurrence.<sup>1,4,5</sup>

The objective of this study is to analyze the feasibility, efficacy and safety of the treatment of pilonidal disease by resection and closure with a Dufourmental flap.

## MATERIAL AND METHODS

A database of 40 patients operated on for sacrococcygeal cysts at the Puerto Belgrano Naval Hospital between January 2020 and January 2021 was retrospectively reviewed. All patients who underwent radical resection and primary closure outside the midline with a Dufourmental flap were included in this study.

The surgical technique is based on the creation of a skin flap adjacent to the affected area, which is moved towards the defect site preserving the original blood supply at the base, ensuring its viability and survival (Fig. 1).

All patients were operated on under spinal anesthesia and in the jackknife position with enhancement of the pelvic region. After marking the segment to be removed and the Dufourmental flap, adhesive tape was placed on the buttocks to separate them from the midline. Radical resection of the lesion up to the presacral fascia was performed and a flap of subcutaneous cellular tissue was created up to the fascia of the gluteus maximus. The defect was closed with 2 skin flaps and a drain was placed (Fig. 2).

Early ambulation was indicated postoperatively and no movement was prohibited. Patients were discharged with a drain, which was removed in the office. Follow-up was performed at 5, 10 and 15 days, with removal of stitches at this last follow-up. Wound care and hair removal of the area were indicated. The last long-term follow-up was performed at 18 months.

Preoperative variables (demographics, form of presentation), operating time and postoperative complications were recorded. Postoperative pain was evaluated during the first postoperative week with a linear visual scale, where 0 was no pain and 10 was the worst pain, recording the highest value in each patient. The time of return to work and recurrence were recorded.

The authors declare no conflicts of interest. Ignacio Ramallo: ramalloignaciof@gmail.com  
Received: March 2023. Accepted: May 2024

Ignacio F. Ramallo: [ORCID https://orcid.org/0000-0001-5139-3586](https://orcid.org/0000-0001-5139-3586), Eliomar Aguilar: [ORCID https://orcid.org/0000-0001-6034-8664](https://orcid.org/0000-0001-6034-8664), Dayana Naranjo: <https://orcid.org/0000-0003-0544-4607>

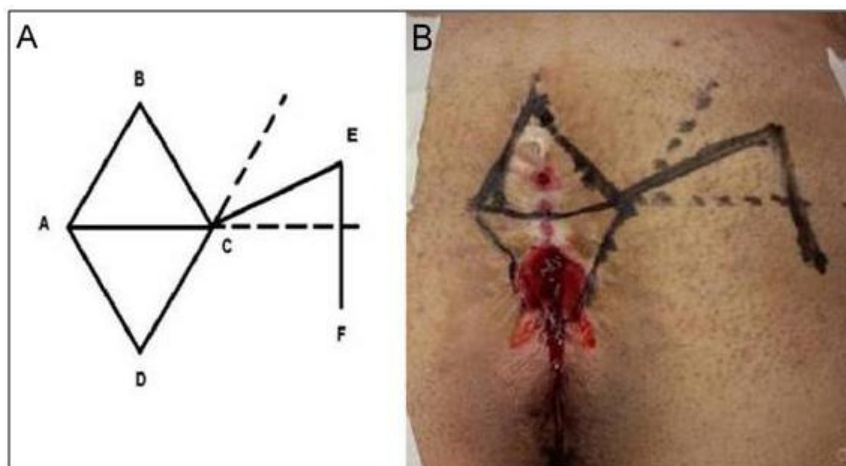


Figure 1. A. Dufourmental flap diagram. B. Marking of the segment to be excised and the flap.

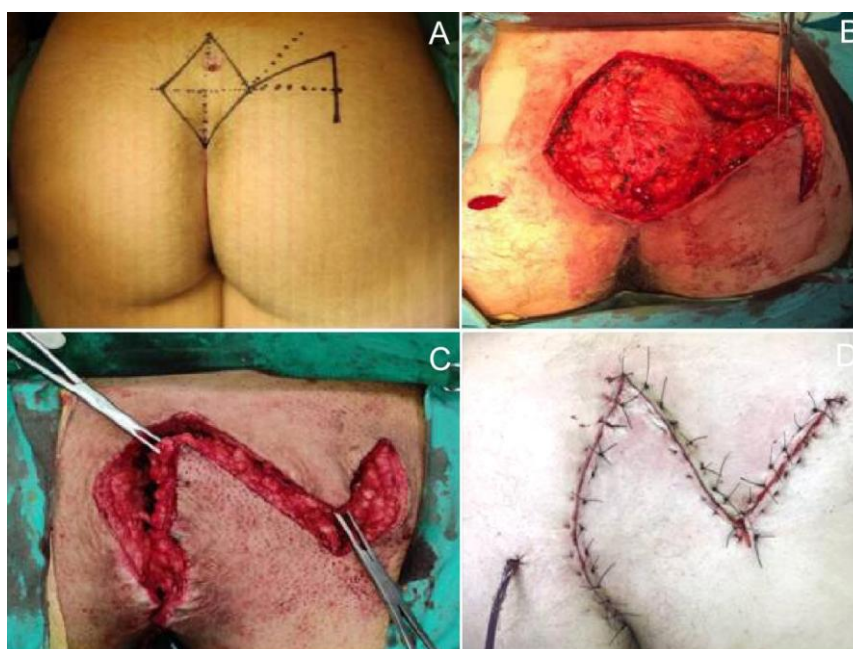


Figure 2. Steps of the surgical technique. A. Marking of the segment to be removed. B. Radical resection up to the presacral fascia. C. Reconstruction of the defect by mobilization of the flap. D. Closure by layers and placement of the drain through a counter incision.

## RESULTS

Ten patients who underwent primary resection and midline closure with a Dufourmental flap were included, of whom 8 were men. The median age was 21.5 (range 16-27) years and the mean BMI was 28.1 (range 22-34) kg/m<sup>2</sup>.

There were 5 patients with discomfort and discharge in the sacral region, 3 patients who had previously required drainage for a sinus abscess (one had an associated perineal fistula), one patient with a first recurrence (previously operated on with the McFee technique) and one patient with a second recurrence (previously with the Karydakis and McFee techniques).

The mean operative time was 64 (range: 45-81) minutes, the mean hospital stay was 1 (range: 1-2) day, the mean time to drain removal was 5.6 (range: 4-7) days, and the mean time to suture removal was 15.5 (range: 14-17) days. The mean maximum postoperative pain score on the visual analogue

scale was 2 (range: 1-4). The mean time to return to work activities was 21.1 (range: 17-30) days. Postoperative morbidity was 20% (2/10 patients): one patient presented 5% necrosis of the upper edge of the flap and a granuloma that was managed conservatively (Fig. 3 A) and another patient (with associated perianal fistula) presented a surgical site infection that required debridement on the 4th postoperative day, evolving with 50% wound dehiscence and healing by secondary intention (Fig. 3 B). In the first case, there were no changes in postoperative management, with return to activities 20 days after surgery. In contrast, in the second case, as wound dehiscence occurred on the 8th postoperative day, the patient was sent to 10 hyperbaric chamber sessions, showing a good response and return to work 30 days after surgery.

After a median follow-up of 18 months, no recurrence occurred.

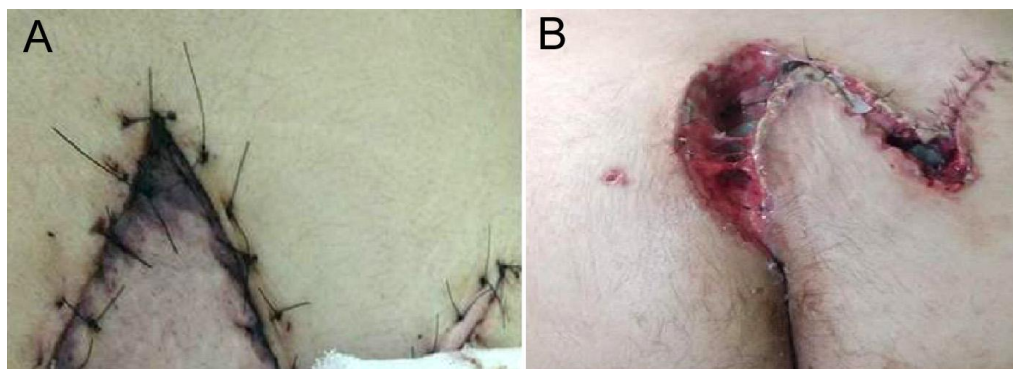


Figure 3. A. Necrosis of the upper edge of the dermocutaneous flap. B. Dehiscence of two-thirds of the surgical wound.

## DISCUSSION

The use of the Dufourmental flap proved to be an effective and safe technique in our series, even in patients with recurrent disease. According to the literature, it offers advantages such as mild postoperative pain, low morbidity and low recurrence rate, as well as early return to work.

Currently, there is no consensus on the ideal surgical alternative applicable in all cases of pilonidal disease. Different recurrence and complication rates have been reported, according to the technique used. The effectiveness of the surgical technique is decisive in this condition that occurs mostly in young patients, in whom the costs generated by the treatment are very relevant.<sup>7</sup>

Primary closure outside the midline (Karydakias/Bascom and Limberg/Dufourmental) is recommended because it offers greater benefits compared to resection techniques with primary closure on the midline, such as lower recurrence (1.4 vs. 10.3%) and lower rate of postoperative infection (6.3 vs. 10.4%). Dehiscence rates for this type of flap vary between 5-10% and necrosis rates between 2-5%,<sup>9</sup> while time to onset of work activities is similar to that for midline closures.<sup>6,8-10</sup>

In our study, the overall complication rate was 20%. This may be due to the inclusion of a patient with associated anal pathology and to the fact that this technique requires a longer learning curve than conventional resection techniques. In addition, it is important to consider that the small sample size may not be very accurate in estimating the actual associated morbidity. However, our morbidity is comparable with that of the literature, which varies between 10-30% for closed techniques and 10-35% for open techniques.<sup>9,10</sup>

Compared with other dermocutaneous flaps, specifically the modified Limberg flap, the Dufourmental flap has better results due to its better degree of rotation that increases the irrigation of the reconstructed site, thus allowing to reduce the risk of ischemia.<sup>9,10</sup> As a disadvantage, it is worth highlighting the longer surgical time and the aesthetic disfigurement. However, due to the less visible location of the scar, this cosmetic inconvenience is surmountable.

## CONCLUSIONS

The Dufourmental flap has proven to be an effective and safe technique for the treatment of pilonidal disease among other closed procedures, even in cases of recurrent disease. Morbidity is similar to that of other conventional techniques. Longer follow-up of this case series and an increase in the number of patients are necessary to perform comparative studies with other techniques in the future.

## REFERENCES

- Lieto E, Castellano P, Pinto M, Zamboli A, Pignatelli C, Galizia G. Dufourmental rhomboid flap in the radical treatment of primary and recurrent sacrococcygeal pilonidal disease. *Dis Colon Rectum*. 2010;53(7):1061-68.
- Mayo OH. Observations on injuries and diseases of the rectum. London: Burgess and Hill; 1833. p. 45-6.
- Karydakias GE. Easy and successful treatment of pilonidal sinus after explanation of its causative process. *Aust N Z J Surg*. 1992; 62(5):385-89.
- Søndena K, Anderson E, Soreide JA. Morbidity and short term results in a randomised controlled trial of open compared to closed treatment of chronic pilonidal sinus. *Eur J Surg*. 1992; 158(6-7):351-55.
- Doll D, Matevosian E, Wietelmann K, Evers T, Kriner M, Petersen S. Family history of pilonidal sinus predisposes to earlier onset of disease and a 50% long-term recurrence rate. *Dis Colon Rectum*. 2009; 52(9):1610-15.
- McCallum IJ, King PM, Bruce J. Healing by primary closure versus open healing after surgery for pilonidal sinus: systematic review and meta-analysis. *BMJ*. 2008; 336(7649):868-71.
- Brasel KJ, Gottesman L, Vasilevsky CA. Members of the Evidence-Based Reviews in Surgery Group. Meta-analysis comparing healing by primary closure and open healing after surgery for pilonidal sinus. *J Am Coll Surg*. 2010; 211(3):431-34.
- Stauffer VK, Luedi MM, Kauf P, Schmid M, Diekmann M, Wieferrich K, et al. Common surgical procedures in pilonidal sinus disease: a meta-analysis, merged data analysis, and comprehensive study on recurrence. *Sci Rep*. 2018;8(1):3058.
- Cai Z, Zhao Z, Ma Q, Shen C, Jiang Z, Liu C, et al. Midline and off-midline wound closure methods after surgical treatment for pilonidal sinus. *Cochrane Database of Systematic Reviews*. 2024, Issue 1. Art. No.: CD015213.
- Hemmingsson O, Binnermark F, Odensten Ch, Rutegård M, Franklin KA, Haapamäki MM. Excision and suture in the midline versus Karydakias flap surgery for pilonidal sinus: randomized clinical trial. *BJS Open*. 2022;6(2):zrac007.