

# Treatment of chronic anal fissure. Late results of anoplasties

Javier Ignacio Villaggi,<sup>a</sup> Agustina Jüül,<sup>b</sup> César Eugenio Quijano<sup>c</sup>  
Sanatorio Parque. Rosario, Argentina.

<sup>a</sup>Surgeon Coloproctologist, accredited teacher, post-graduate course of Specialist in General Surgery, UNR.

<sup>b</sup>Surgeon.

<sup>c</sup>Surgeon Coloproctologic, Instituto Cardiovascular de Rosario (ICR). Researcher, Centro Rosarino de Estudios Perinatales.

## ABSTRACT

**Introduction:** Anal fissure is a tear of the ectodermal anal mucosa. It manifests with intense local pain and is a common but under-diagnosed condition. It can present acutely and heal with the appropriate medical treatment, although if it is not well established it can evolve into a chronic anal fissure complex. Its most important causes are thick and hard stools, as well as other anal trauma. Sphincter hypertonia, which can be the cause or consequence of trauma, also produces local ischemia that makes healing difficult.

**Design:** Retrospective and descriptive study.

**Material and methods:** Between 2010 and 2018, 168 patients (58.3% women, 41.6% men, age range between 28 and 72 years) with primary chronic anal fissure were operated on. They all had bowel preparation. Under general anesthesia, fissurectomy was performed. After identification and preservation of the anal sphincter, a subcutaneous pedicle skin flap was carved, slid, and anchored to the pectinate line.

**Results:** After discharge, 85% of the patients did not require analgesic rescue. No patient reported horrible or extremely intense pain. The mean healing time was 5 (range: 4-8) weeks. There was no recurrence or persistence of the fissure, or anal incontinence.

**Conclusions:** Patients with chronic anal fissure can be treated with a subcutaneous pedicle anal skin flap with good results. Anoplasty is a simple, reproducible, well-tolerated technique with low postoperative pain and high cure rates. Its greatest benefit is that it does not cause anal continence disorders with high long-term satisfaction. Therefore, it should be taken into account by the coloproctologist for the treatment of primary chronic anal fissure.

**Keywords:** Anal Fissure; Fecal Incontinence; Anoplasty

## INTRODUCTION

Anal fissure is a tear of the ectodermal anal mucosa, usually a few millimeters long (<10 mm), extending from the anocutaneous border to the pectinate line, rarely involved.<sup>1</sup> It is located more frequently at the junction of the posterior quadrants (9 out of 10 patients), and can also be para-commissural (1 out of 10 patients), more frequent in females.<sup>2,3</sup> Anal fissure is a very frequent pathology in our environment and at the same time under-diagnosed.

Clinically, it presents with severe anal pain that is exacerbated during defecation and may be accompanied by mild bright red bleeding. On digital examination, when it can be performed, sphincter hypertonia at rest is found in the vast majority of cases. Two types of fissures are distinguished: 1) Acute, which with well-established medical treatment evolve towards healing in less than 6 weeks, and 2) Chronic, in which the lack of healing determines the appearance of the chronic anal fissure complex characterized by a triad consisting of the sentinel hemorrhoid, the fissure with raised edges and the hypertrophic papilla<sup>4</sup> (Fig. 1).

*The authors declare no conflicts of interest.*

Agustina Jüül

agus.juul@gmail.com

Received: August 2021. Accepted: March 2022.

The etiology is unclear and possibly multifactorial. The vast majority of patients refer to the evacuation of thick and hard stools, or another type of anal trauma as an event prior to the onset of symptoms.<sup>5</sup> Sphincter hypertonia has been mentioned since the first reports and has been documented by manometry in multiple studies, but it is not clear whether it is cause or consequence of the trauma.<sup>6-8</sup> Another theory states that a severe spasm of the sphincter produces an area of ischemia that makes healing difficult.<sup>9</sup> Since the publication of Eisenhammer<sup>10</sup> in 1951 and later of Notaras,<sup>11</sup> contracture of the internal anal sphincter is considered as a triggering factor for the fissure, which clinically translates into its hypertonia. Therefore, open or closed lateral internal sphincterotomy (LIS) is proposed as the standard surgical procedure. However, other authors question this because postoperative incontinence can occur in 1 to 47% of cases, which is often under-diagnosed by the surgeon.<sup>12,13</sup> A Cochrane systematic review published by Nelson et al.<sup>14</sup> in 2011, with randomized trials that evaluated the appearance of fecal incontinence after sphincterotomy, revealed a mean risk of 10%. In anoplasties the anal sphincters are not manipulated, so the risk of incontinence is very low or nil.<sup>15</sup>

In this study we present our experience in the treatment of primary chronic anal fissure by sliding a skin flap on a subcutaneous pedicle, as recommended by Drs. Galván<sup>16</sup>

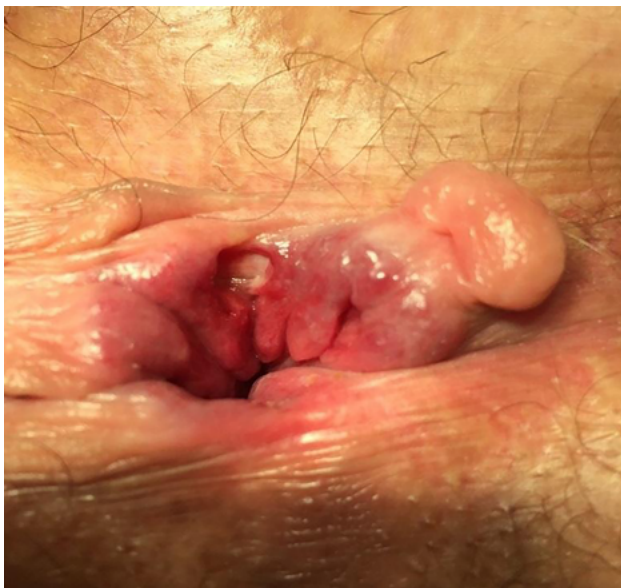

Figure 1: Chronic anal fissure complex: sentinel hemorrhoid, fissure with raised edges and hypertrophic papilla.

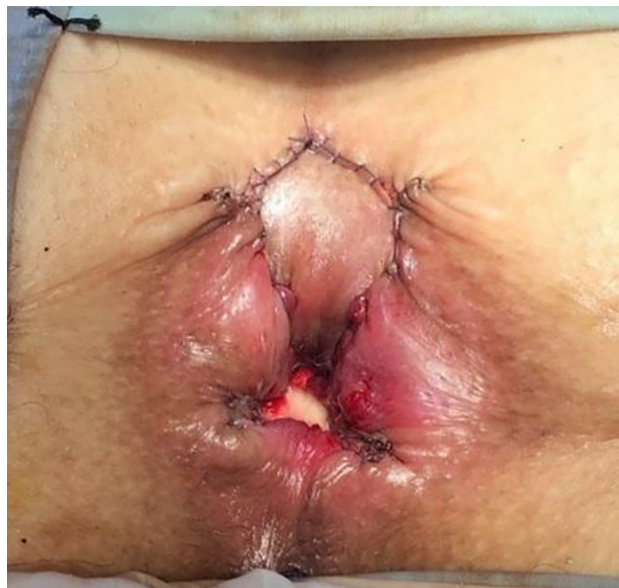

Figure 3: Subcutaneous pedicle skin flap completely sutured.

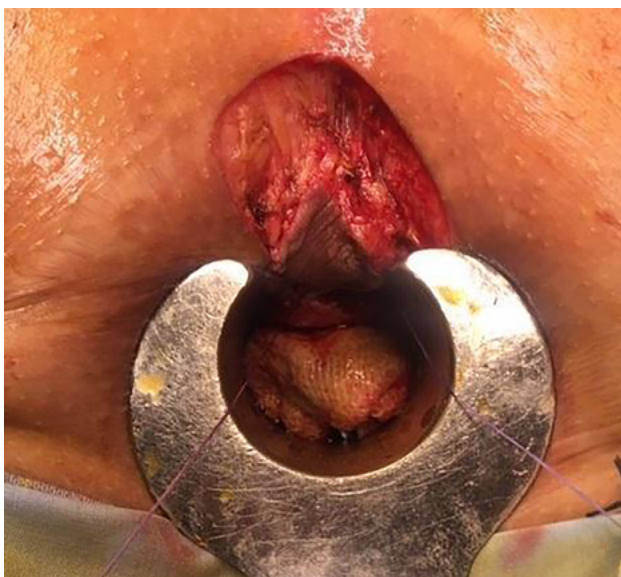

Figure 2: House flap carved and sutured to the pectinate line.

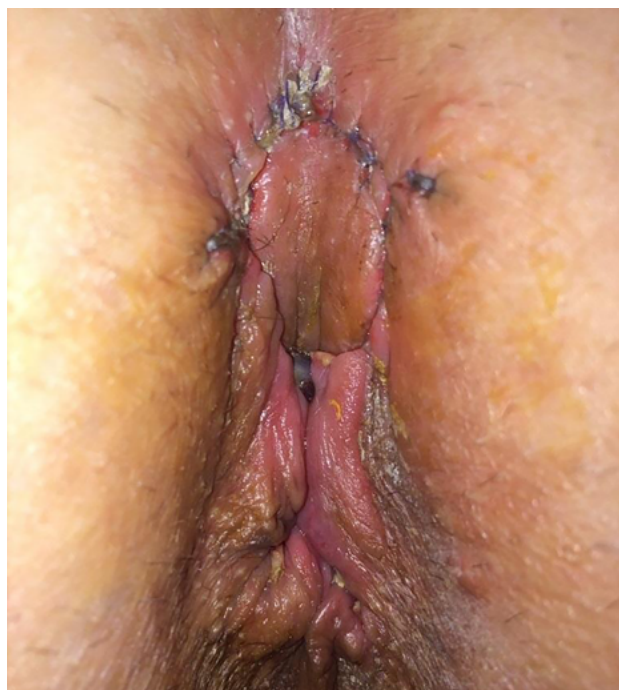

Figure 4: Postoperative control of anoplasty.

and Villaggi Leiva,<sup>17</sup> a technique that we consider an alternative to internal lateral sphincterotomy.

## MATERIAL AND METHODS

The study was conducted in patients of both sexes, older than 18 years who presented primary chronic anal fissure. Exclusion criteria were: patients with previous proctological surgery, stenosis with fissure and fissure after LIS. Also those who presented some degree of previous incontinence. The demographic data of the patients operated on between January 2010 and January 2018 were collected retrospectively from the Sanatorio Parque database of medical records. All patients underwent bowel prepara-

tion with a picosulfate enema the night before the procedure, that was carried out under general anesthesia and in jackknife position. A dose of antibiotic was administered during anesthetic induction and continued until the 7th postoperative day according to the protocol of the Infectious Diseases Committee of the institution. Fissurectomy was performed, after identification of the internal anal sphincter, which was respected, a skin "house" flap was carved, slid and anchored at the level of the pectinate line with a 5-0 Vicryl running suture (Figs. 2, 3 and 4).

All patients were hospitalized for one day. Postoperative analgesia with diclofenac 150 mg was indicated to be passed intravenously in 24 hours during their hospital stay. At the time of discharge, patients were prescribed diclofenac 50 mg + paracetamol 500 mg every 8 hours and rescue with ketorolac 20 mg or tramadol 50 mg as needed due to pain intensity.

The patients were discharged the day after surgery with precise indications of hygienic-dietary care. A diet rich in fiber was recommended and in those cases that did not achieve a bowel movement within the first 48 hours, a laxative based on picosulfate + magnesium was indicated.

The amount of analgesics required, the need for rescue with opiates and the degree of patient satisfaction were analyzed using the McGill pain questionnaire, where 0 is the absence of pain, 1 discomfort, 2 mild pain, 3 disturbing pain, 4 horrible pain and 5 extreme pain.<sup>18</sup> Postoperative complications, degree of postoperative incontinence according to the Wexner scale and healing time were also analyzed.

## RESULTS

A total of 168 patients underwent surgery for chronic primary anal fissure, of which 98 were women (58.3%) and 70 men (41.7%) (Fig. 5), with an age range between 28 and 72 years.

In 73 (43%) patients only anoplasty was performed, while in 95 (57%) hemorrhoidectomy was associated.

Of the 168 patients, 85% did not require rescue analgesics, 14% required post-defecation rescue with ketorolac, and 1% with tramadol. None required the use of IM or IV analgesics for pain relief after discharge (Table 1).

The degree of satisfaction based on the satisfaction questionnaire (McGill pain) showed that 88% of the patients presented a score of 1 and only 1% a score of 3. No patient reported horrible or extreme pain (Table 2).

No degree of incontinence was found one year after the procedure according to the Wexner scale.

Healing time ranged from 4 to 8 weeks, with a median of 5 weeks; 5.3% of the patients presented a partial lateral detachment of the flap, which only delayed healing, and in 33.3% the donor area was opened without any clinical implication (Table 3). Those patients with associated hemorrhoidectomy did not present greater postoperative pain or delayed wound healing.

There was no recurrence or persistence of the fissure.

## DISCUSSION

The classic treatment of chronic anal fissure is the open or closed internal lateral sphincterotomy described in 1835

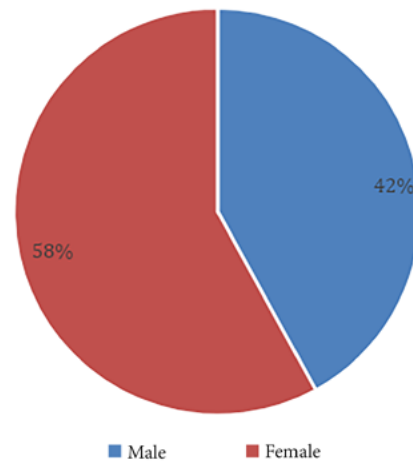


Figure 5: Distribution of patients by sex.

TABLE 1: POSTOPERATIVE ANALGESIC RESCUE REQUIREMENT

Analgesic rescue	n	%
None	143	85
Ketorolac	23	14
Tramadol	2	1

TABLE 2: PAIN INTENSITY ACCORDING TO MCGILL SCALE

Score	n	%
1	148	88
2	18	11
3	2	1

TABLE 3: POSTOPERATIVE HEALING

Type of healing	n	%
Complete	103	61,3
Dehiscence of donor area	56	33,3
Partial lateral detachment	9	5,3

by Brodie, a technique that currently remains as the gold standard despite having undergone some modifications. It has a 90-100% success rate, with a high level of patient satisfaction. However, the recurrence rate ranges between 3 and 8%, fecal incontinence between 2 and 23% and flatus incontinence reaches 46%.<sup>19,20</sup>

Advancement flap anoplasty was described in our setting in the 1960s by different authors who used it for the treatment of anal stenosis, chronic anal fissure, and posterior hemorrhoidectomies. Anoplasty can be performed equally in the presence of hypertonia and hypotonia of the sphincters.

In our series, in addition to presenting very good tolerance, the patients did not present any postoperative

ve incontinence, which is logical since the internal anal sphincter is not manipulated with this technique.

The success rate was 100%. The most frequent complication was flap detachment, but this did not change the success of the procedure. Although the patients commented that the postoperative period was long and required a lot of care, they also stated that they would recommend this treatment to a family member or friend with a similar condition.

A comparative study between anoplasty and LIS in patients with chronic anal fissure has recently been published, showing that the group undergoing anoplasty without sphincterotomy had an incontinence rate of 2% compared to 14% in the group with LIS.<sup>25</sup> In any case,

we consider that it is necessary to carry out more comparative studies between both techniques.

## CONCLUSION

From the analysis of the results of this series we can conclude that patients with chronic anal fissure can be treated with a pedicled subcutaneous anal skin flap with good results. Anoplasty is a simple, reproducible, well-tolerated technique with low postoperative pain and high cure rates. Its greatest benefit is not causing anal continence disorders with high long-term satisfaction. For these reasons, sliding flap anoplasty should be considered by the coloproctologist for the treatment of primary chronic anal fissure.

## REFERENCES

1. Herzig DO, Lu KC. Anal Fissure. *Surg Clin North Am* 2010; 90:33-44.
2. Lu KC, Herzig DO. Anal fissure. In: *The ASCRS Textbook of Colon and Rectal Surgery*. Steele SC, Hull TL, Read TE, Saclarides TJ, Senagore AJ, Whitlow CB (eds). 3rd ed. Springer: Arlington Heights. 2018:205-14.
3. Latif JA., Rodriguez Martin JA., Hequera JA. Urgencias en enfermedades del colon, recto y ano. *Akadia: Buenos Aires*. 2014:330-339.
4. Yeo Charles J. Shackelford's *Surgery of The Alimentary Tract*. 3rd ed. Panamericana: Buenos Aires. 1993:350-51.
5. Douglas W Mapel, Michael Schum y Ann Von Worley. La epidemiología y tratamiento de la fisura anal en una cohorte de base poblacional. *BMC Gastroenterología* 2014 14:129-136.
6. Goligher J. *Surgery of the Anus, Rectum and Colon*. Bailliere Tindall: Londres.1991:143-44.
7. Farouk R, Duthie GS, Mac Gregor AB, Bartolo DC. Sustained internal sphincter hypertonia in patients with chronic anal fissure. *Dis Colon Rectum* 1994; 37:424-29.
8. Gibbons CP, Read NW. Anal hypertonia in fissures: cause or effect? *Br J Surg* 1986; 73:443-52.
9. Schouten WR, Briel JW, Auwerda JJ, De Graff EJ. Ischemic nature of anal fissure. *Br J Surg* 1996; 83:63-5.
10. Eisenhammer S. Surgical correction of chronic internal anal (sphincteric) contracture. *S Afr Med J* 1951; 25:486-9.
11. Notaras MJ. Lateral subcutaneous sphincterotomy for anal fissure a new technique. *Proc R Soc Med* 1969; 62:713.
12. Garg P, Garg M, Menon GR. Long term continence disturbance after lateral internal sphincterotomy for chronic anal fissure: a systematic review and meta-analysis. *Colorectal Dis* 2013;15 104-17.
13. Casillas S, Hull TL, ZutshiM, Trzcinski R, Bast JF, Xu M. Incontinence after a lateral internal sphincterotomy: are we underestimating it? *Dis Colon Rectum* 2005; 48: 1193-99.
14. Nelson RL, Chattopadhyay A, Brooks W, Platt I, Paavana T, Earl S. Operative procedures for fissure in ano. *Cochrane Database Syst Rev* 2011: CD002199.
15. Nyam DC, Wilson RG, Stewart KJ, Farouk R, Bartolo DC. Island advancement flaps in the management of anal fissures. *Br J Surg* 2005; 82:326-28.
16. Galván ES. Técnica plástica para el tratamiento de la fisura de ano. *Prensa Med Argent* 1972; 50:613-15.
17. Villaggi Leiva JC. Actas IX Congreso Latinoamericano de Proctología (ALAP). I Congreso Chileno de Colproctología, Santiago, 1984: 34-37.
18. Melzack R. The short-form McGill Pain Questionnaire 1987; 30:191-97.
19. Elsebae MM. A study of fecal incontinence in patients with chronic anal fissure: prospective, randomised, controlled trial of the extent of internal anal sphincter division during lateral sphincterotomy. *World J Surg* 2007; 31:2052-57.
20. Garcia-Aguilar J, Belmonte C, Wong WD, Lowry AC, Madoff RD. Open vs closed sphincterotomy for chronic anal fissure: long-term results. *Dis Colon Rectum*; 1996;39:440-43.
21. Musiari J. Estenosis de ano. *Sem Med* 1954;104:883-84.
22. Heidenreich A, Zavaleta D. Estenosis anal. *Rev Argent Cirug* 1970;19:397-401.
23. Cabral Arrayagaray AM, Rodriguez JR. Plásticas en cirugía orificial. *Prensa Med Argent* 1977; 64:200.
24. Sarner JB. Plastic relief of anal stenosis. *Dis Colon Rectum* 1969;12:277-80.
25. Magdy A, El Naked A, el Food Y, Youssef M, Farid M. Comparative study of conventional lateral internal sphincterotomy, V-Y anoplasty, and tailored lateral internal sphincterotomy with V-Y anoplasty in the treatment of chronic anal fissure. *J Gastroenterol Surg* 2012;16:1955-62.